

Pediatrics

Torsion in a right undescended testis: A case report

Aulia Ladies Melani^a, Muhammad Faruk^b, Muhammad Asykar Palinrunji^{a,c,*}^a Department of Surgery, Andi Makkasau Hospital, Pare-Pare, Indonesia^b Department of Surgery, Faculty of Medicine, Universitas Hasanuddin, Makassar, Indonesia^c Division of Urology, Department of Surgery, Faculty of Medicine, Universitas Hasanuddin, Makassar, Indonesia

ARTICLE INFO

Keywords:

Testicular torsion
Undescended testis
Inguinal cryptorchidism
Orchiectomy

ABSTRACT

Testicular torsion in undescended testicles (UDTs) is a rare clinical combination. Symptoms can be ambiguous and misinterpreted as indications of other common conditions. Moreover, late identification of a UDT may significantly delay the diagnosis and lead to adverse outcomes. Here, we report a case of a 16-year-old boy with progressive pain in the right inguinal region and a history of right UDT. Intraoperatively, he was diagnosed with testicular torsion, and an orchiectomy was performed. This report also underscores the importance of an early UDT torsion diagnosis.

1. Introduction

An undescended testis (UDT) is a condition where the testicles are not found in the scrotal sac. It has an incidence of around 0.8%–1% of births and is often asymptomatic.¹ Several genetic mutations are associated with maldescended testes in an unusual position.² Testicular torsion can occur at any age, but it is considered unlikely under UDT conditions after the first year of life.³ Torsion of a UDT is a surgical emergency whose frequency may be underestimated in the pediatric population.⁴ We report a case with torsion in the right UDT inguinal location.

2. Case presentation

A 16-year-old boy attended the urology clinic with progressive pain in the right inguinal region for two days, accompanied by nausea and a persistent lump in the right groin. He had no fever, painful urination, or change in defecation pattern. He also had a history of a UDT on the right side of the scrotal sac.

On physical examination, the patient looked moderately ill. His vital signs were within normal limits. There was a palpable lump in the right groin measuring 2 × 2 × 1 cm; its consistency was solid, fixed, and tender. A testicle was palpable on the left side of the scrotum.

His serum white blood cell count was 11,800/μL; the other blood parameters were within normal limits. Doppler ultrasound of the right groin showed a mass of about 2 cm in diameter in the right inguinal

canal and no sign of blood flow. The epididymis was enlarged with minimal vascularization, and a whirlpool sign was observed in the spermatic cord (Fig. 1). Surgical exploration was conducted in the right inguinal area, and a black-colored torsion testicle was found in the inguinal canal (Fig. 2). It was decided to perform an orchiectomy. The patient was discharged in good condition on postoperative day two. There were no complaints at the follow-up one week postoperative.

3. Discussion

Cryptorchidism is an inherited disorder in which the testicles fail to descend into the scrotum in newborns.³ A UDT may be located in the upper scrotum, the superficial inguinal pouch, the inguinal canal, and the abdomen. About 70% of UDT are palpable and 30% are non-palpable. For non-palpable UDTs, Fifty-five percent are intra-abdominal, 30% are in the inguinal-scrotal area, and 15% are vanishing or absent.⁵

Testicular torsion is a diagnostic and therapeutic emergency that must be treated urgently to save the testis because of the high risk of damage to spermatogenic and Sertoli cells within the four-hour ischemia period.³ The etiology of torsion in UDTs is unknown. However, it might be associated with abnormal contraction of the cremaster muscle or gubernacular attachment, or undescended testicular size.^{1,3}

Clinical symptoms of UDT torsion include local pain in the testicular area, nonspecific abdominal pain, and nausea, possibly with vomiting. Its physical indications include swelling in the inguinal area and

* Corresponding author. Division of Urology, Department of Surgery, Faculty of Medicine, Universitas Hasanuddin, Jalan Perintis Kemerdekaan KM 11, Makassar, South Sulawesi, 90245, Indonesia.

E-mail addresses: aualadies@gmail.com (A.L. Melani), muhhammadfaruk@unhas.ac.id (M. Faruk), apalinrunji@yahoo.com (M.A. Palinrunji).

<https://doi.org/10.1016/j.eucr.2023.102480>

Received 24 May 2023; Received in revised form 20 June 2023; Accepted 23 June 2023

Available online 23 June 2023

2214-4420/© 2023 The Authors. Published by Elsevier Inc. This is an open access article under the CC BY-NC-ND license (<http://creativecommons.org/licenses/by-nc-nd/4.0/>).

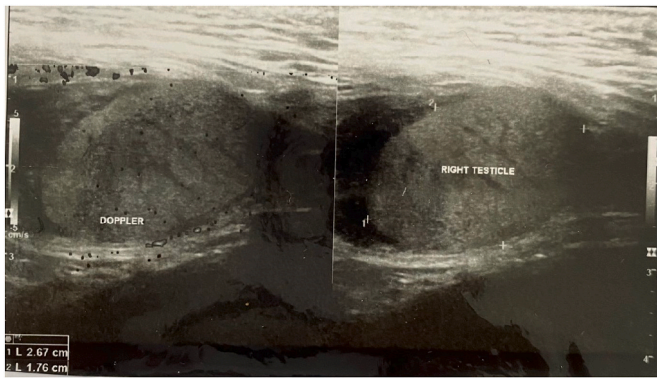


Fig. 1. Doppler ultrasound images show a right inguinal testicle, a mass of about 2 cm in diameter in the right inguinal canal with no sign of blood flow.

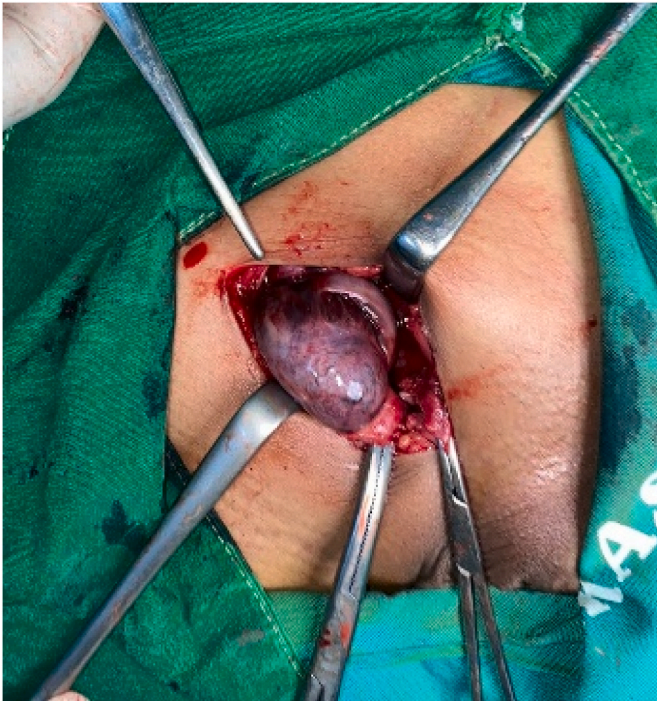

Fig. 2. A perioperative image shows the black-colored testicular torsion found in the inguinal canal.

erythema, a hard or soft mass in the inguinal area, and an empty ipsilateral hemiscrotum.⁴

However, uncommon presentations of UDT torsion are a diagnostic dilemma that can delay surgical treatment, leading to irreversible necrosis and adverse outcomes,¹ especially when accompanied by a lack of awareness by health professionals and patients that exacerbate the delay.²

Imaging studies such as Doppler ultrasound of the testes, computed tomography, and technetium-99 m scrotal scintigraphy can provide more detailed results. On Doppler ultrasonography, a torsioned testicle will have an avascular appearance with a hyperemia area around it.³

The sooner a patient with torsion is diagnosed and managed, the better their prognosis. However, salvage rates with torsion in UDTs have historically been poor (around 10%) compared to torsion in normally descended testes (around 70%) when treated within 12 hours.³ Therefore, orchiectomy is preferred in most adult cases of UDT torsion.

4. Conclusion

Testicular torsion in UDTs correlates with poor outcomes. This report underscores the importance of early UDT torsion diagnosis.

Consent

Written informed consent was obtained from the child's parents or guardians for publication of this case report and accompanying images. A copy of the written consent is available for review by the Editor-in-Chief of this journal on request.

Funding

No funding or sponsorship was received for this study or publication of this article.

Declaration of competing interest

The authors declare that they have no conflict of interests.

References

1. El Moudane A, Ouraghi A, Mokhtari M, Boukhannous I, Barki A. Acute abdomen revealing a testicular torsion of an undescended testis "case report.". *Urol Case Rep.* 2022;42, 102035. <https://doi.org/10.1016/j.eucr.2022.102035>.
2. Reed B, Banerjee R, Tsampoukas G, Gray R. Testicular torsion in an undescended testicle: chasing a diagnosis. *J Surg Case Rep.* 2022;2022(6):rjac263. <https://doi.org/10.1093/jscr/rjac263>.
3. Geng J-H, Huang C-N. Torsion of undescended testis: clinical, imaging, and surgical findings. *Urol Sci.* 2014;25(1):31–34. <https://doi.org/10.1016/j.urols.2013.05.007>.
4. Kargl S, Haid B. Torsion of an undescended testis — a surgical pediatric emergency. *J Pediatr Surg.* 2020;55(4):660–664. <https://doi.org/10.1016/j.jpedsurg.2019.06.018>.
5. Naouar S, Braiek S, El Kamel R. Testicular torsion in undescended testis: a persistent challenge. *Asian J Urol.* 2017;4(2):111–115. <https://doi.org/10.1016/j.ajur.2016.05.007>.